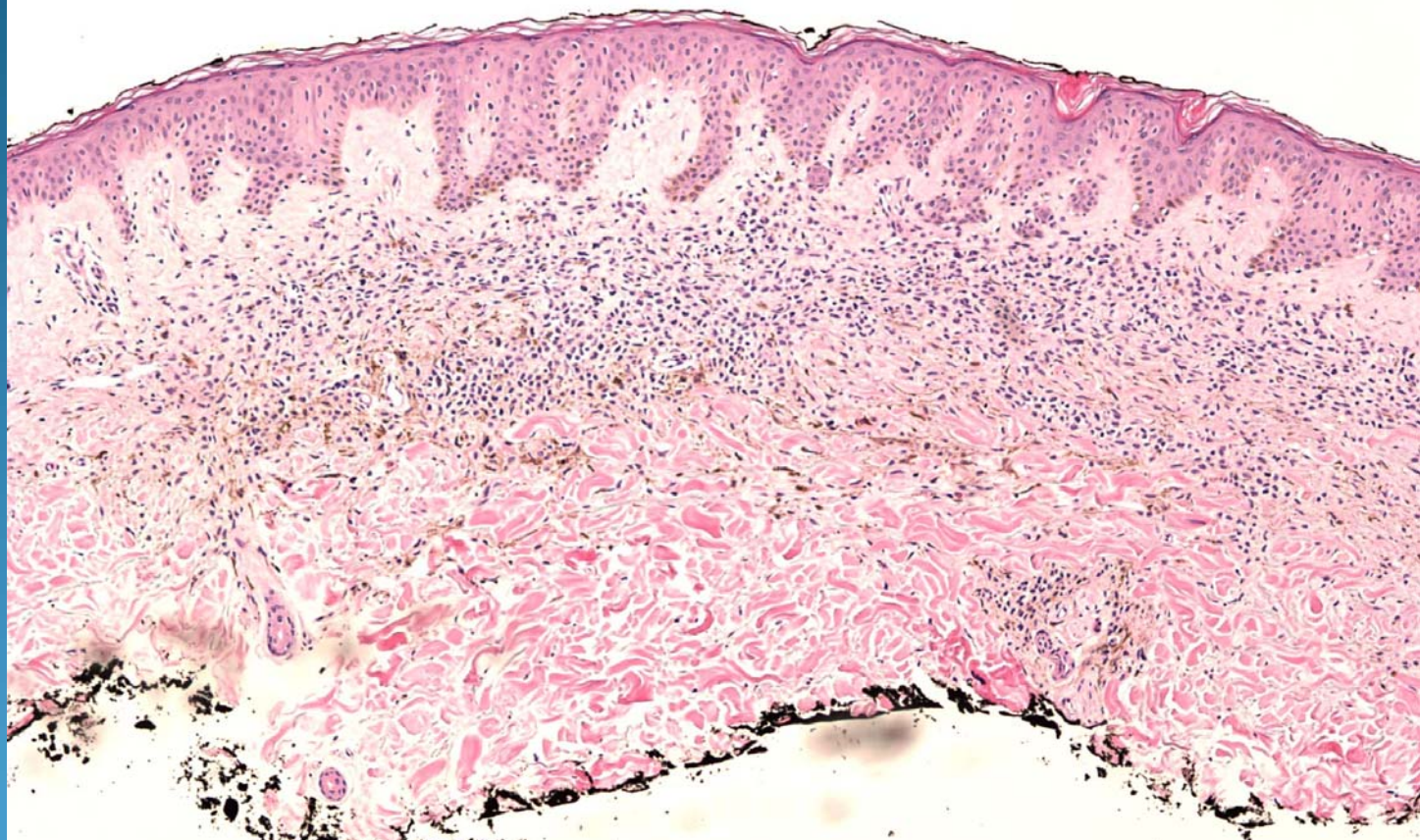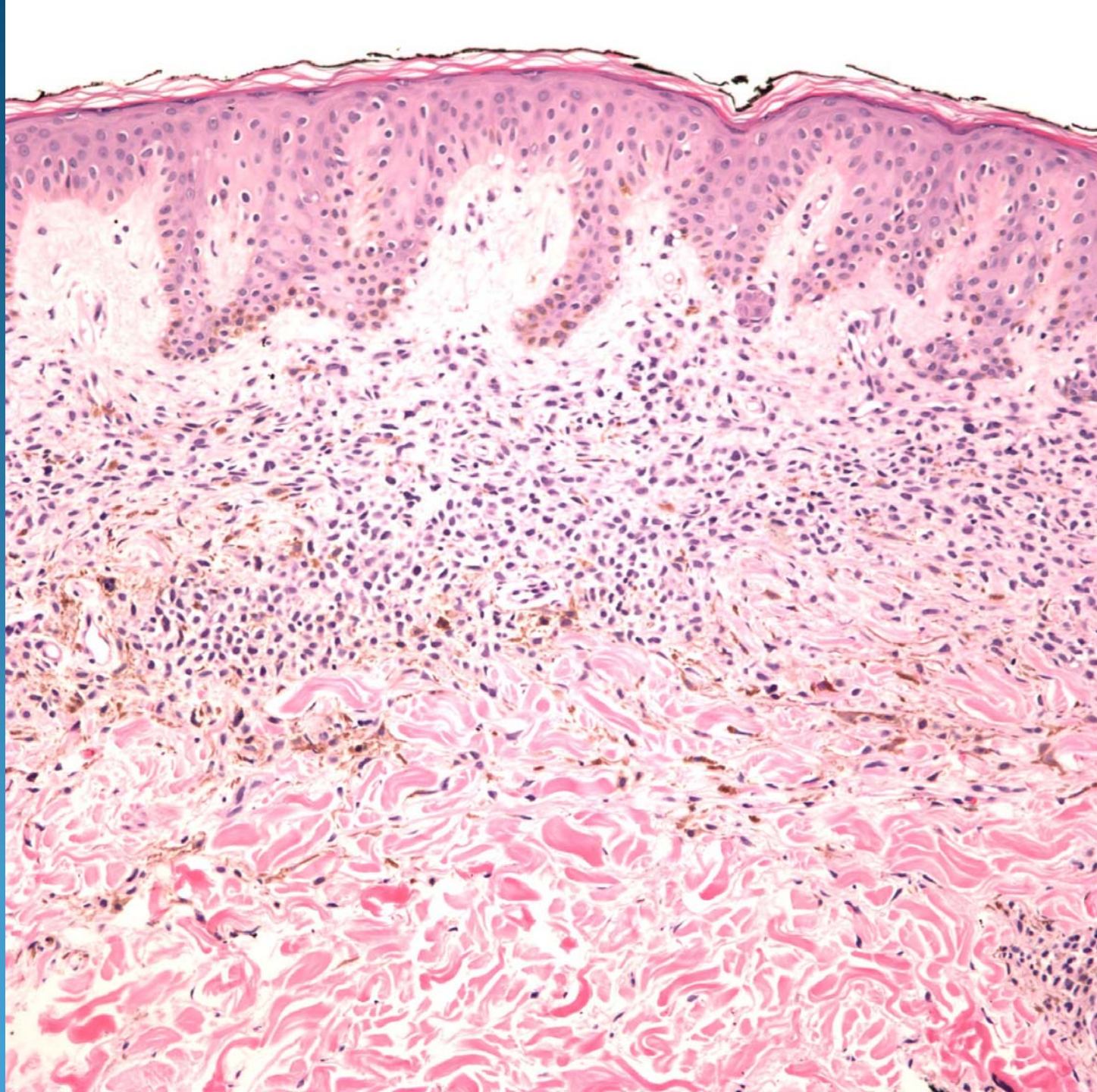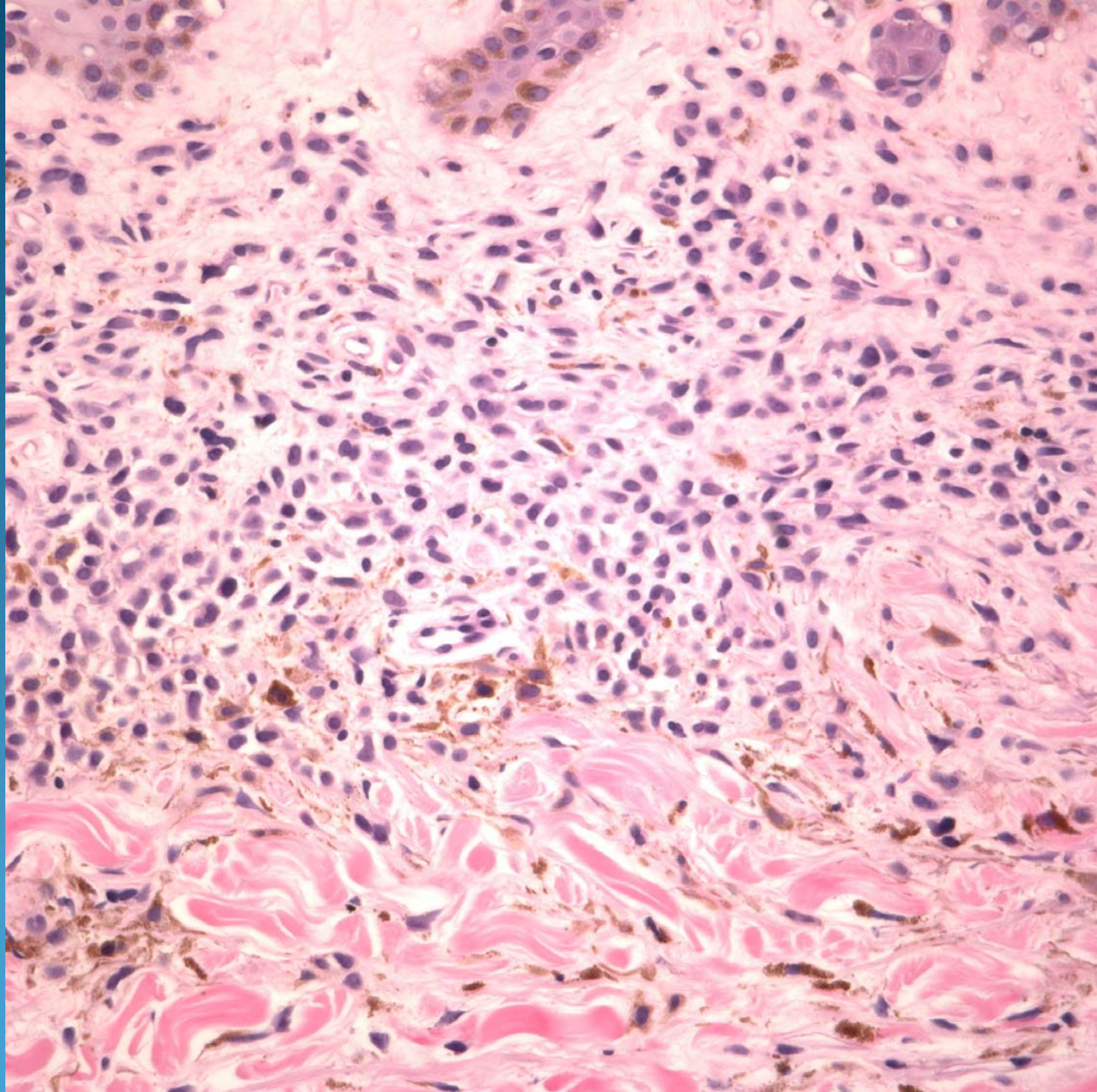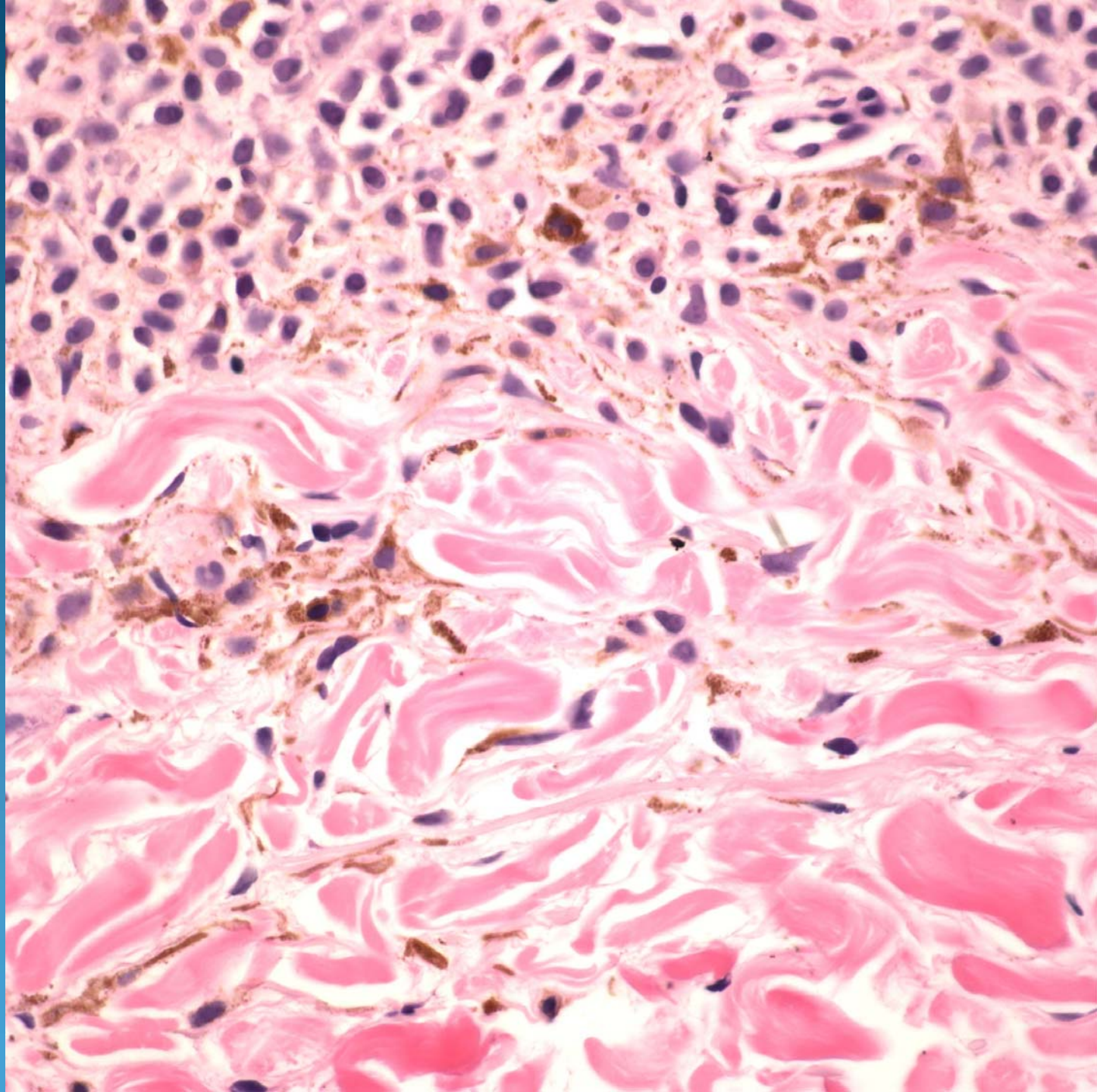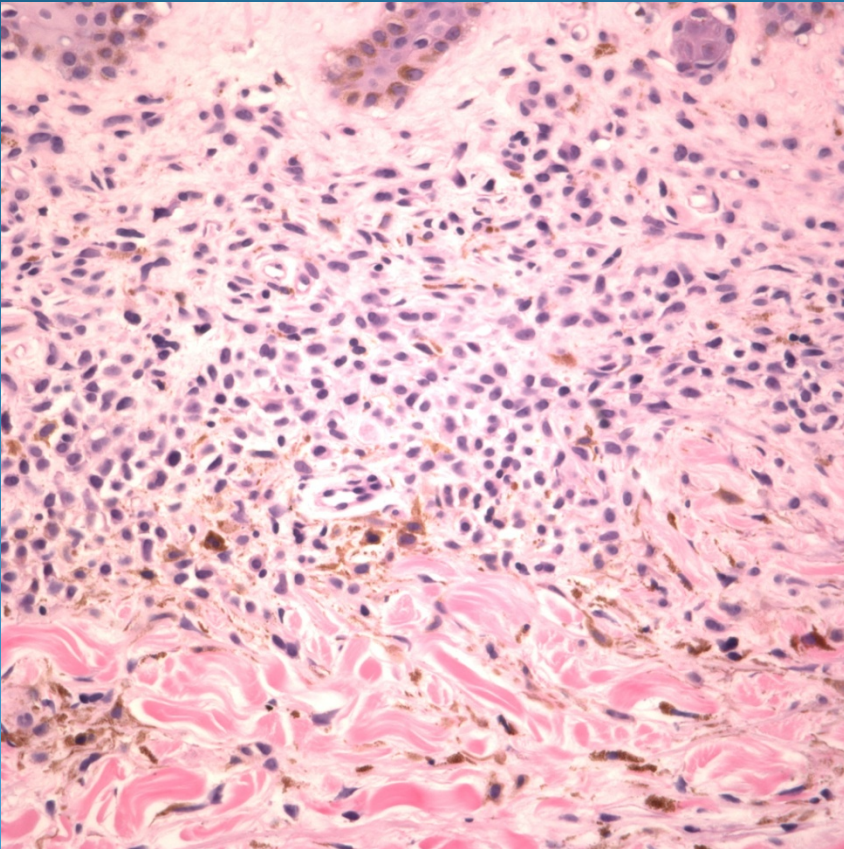


Combined Nevus

Pearls



- Conventional melanocytic nevus combined with one or more melanocytic nevus variant
- Most common combinations include blue nevus, desmoplastic nevus, and Spitz nevus